

BODY DIAGRAM HEAD

Right

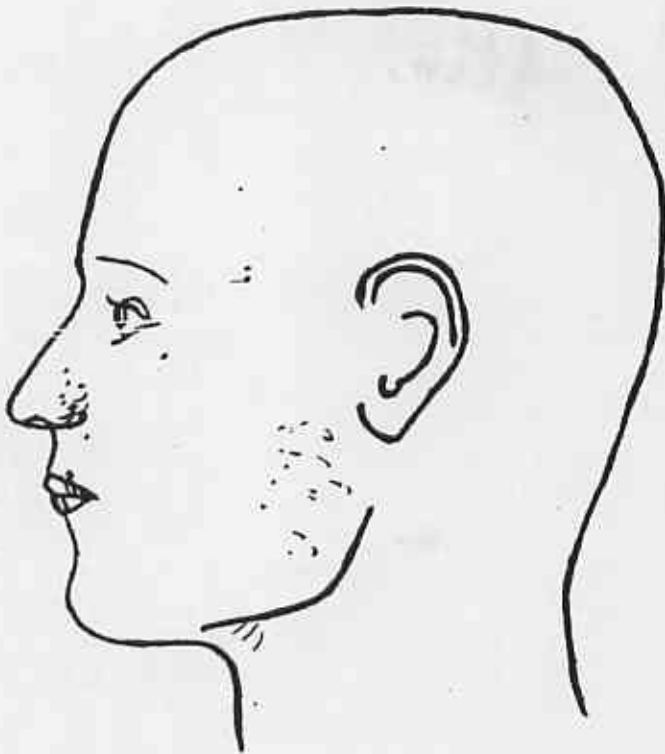
abrasions up & low lips

abrasions


petechiae

red abrasions upper & lower lip

Left




fract  
2 hem. left side of tongue



1/4 2 hem post pharynx mucosa, rt side which extends to aerosal surface

1/4 2 hem post. aspect posterior pharynx at side  
laryngeal petechiae



Decedent's Name Johanna Vega

Examined by Margaret Prial

Date 3/19/99

Case Number Bx 99-2858

City of New York

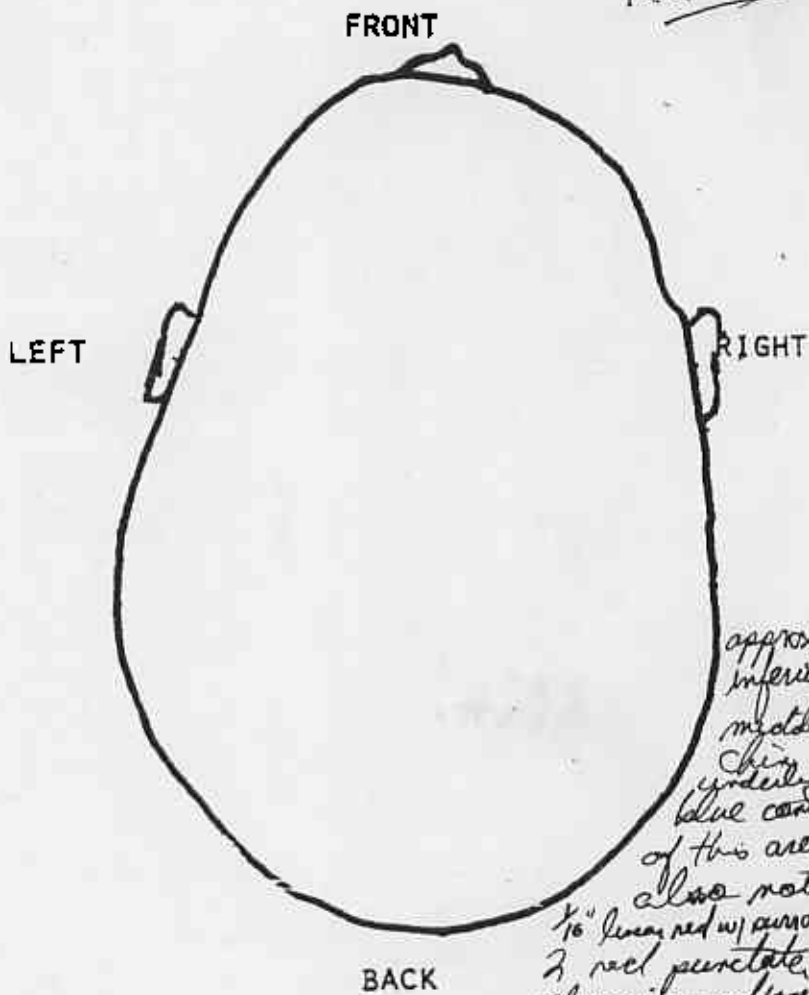
City of New York

DEPARTMENT OF HEALTH  
OFFICE OF THE CHIEF MEDICAL EXAMINER

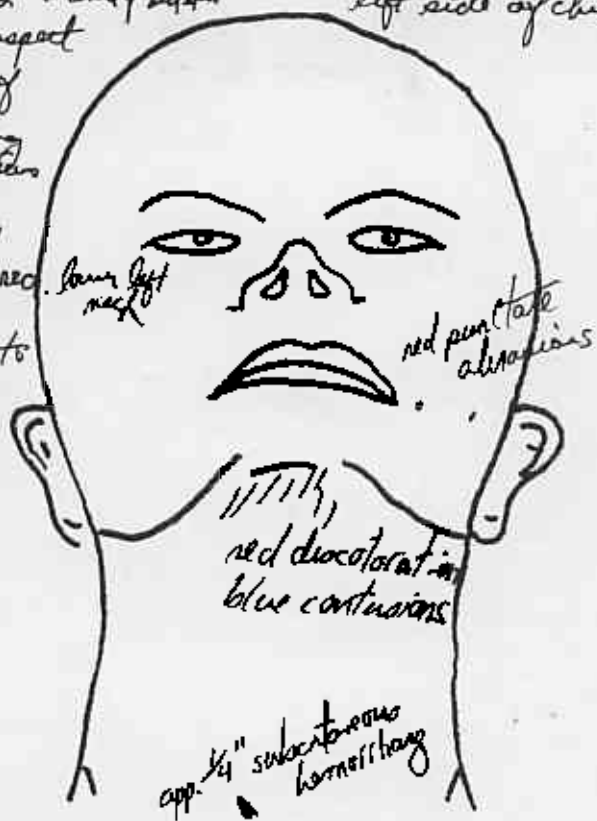
Head and Neck:

Abraisions:

app 1" x 7" red abrasion  
overlying rt cheekbone  
multiple small red abrasions  
of Rt and left noses  
multiple confluent and  
confluent red abrasions  
of upper and lower lip  
2 approx 1/4" abrasions  
at side of mouth and chin  
1 approx 1/4" red abrasion  
overlying rt side of nose  
approx 1/8" linear red abrasion  
surrounded by red skin  
left side of chin



approx 1/2 x 1" area of reddish  
inferior aspect  
middle of  
chin  
underlying  
blue contusion  
of this area  
also noted  
1/8" linear red w/ surround red  
2 red punctate  
abrasions adjacent to  
l. corner of mouth and  
on l. cheek



Contusions:

Cluster of several small approx 1/8" blue contusion  
at side of forehead near hairline  
small blue contusion at eyelid

Petechiae:

Large out of petechiae overlying  
lower lateral aspect of left cheek  
and upper aspect left side of  
neck covering approx 2" x 2"  
several petechiae rt cheek

Mouth:

2 small red abrasions of upper gums (just abv)  
to rt central and lateral incisors (opposite)  
3 small contusions/petechiae inner aspect upper  
lip

Decedent deJhanna Vega

Pathologist: Allegant Prill

Case No. R-99-2858 Date 8/19/99

2 small contusions <sup>lateral aspect or left side</sup> inside aspect upper lip.  
large contusion <sup>left side</sup> inner lower lip and gums

2 fresh hem. left side of tongue:  
approx  $\frac{1}{4}$  lateral aspect l. side tongue  
approx  $\frac{1}{4} \times \frac{1}{8}$  hem anterolateral aspect l. side

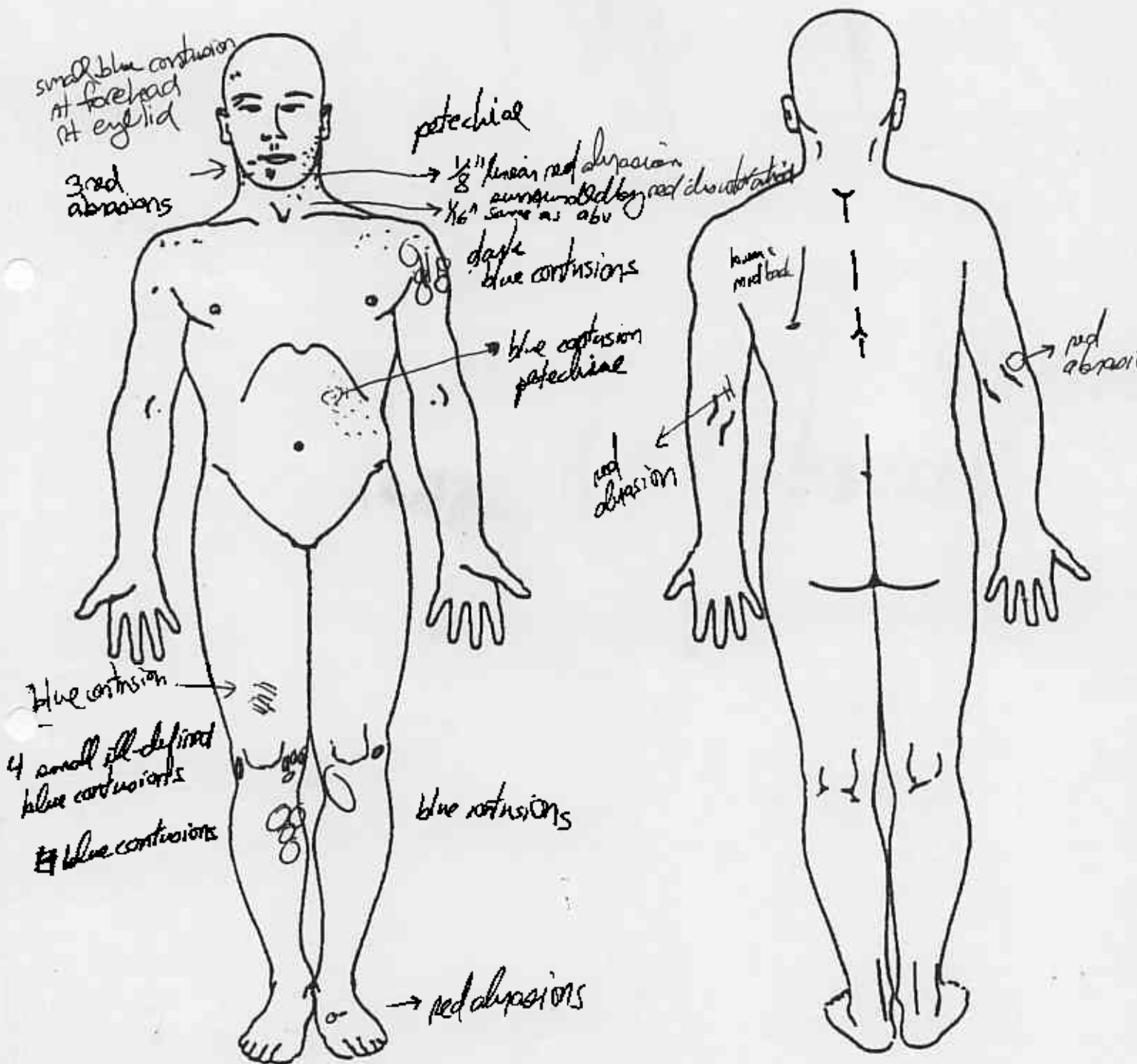
app  $\frac{1}{4}$ " hem rt. side post pharyngeal muscle mucosa and serosa  
 $\frac{1}{4}$ " " inferior ~~to~~ and medial to that described abv.

several petechiae larynx

small app  $\frac{1}{4}$ " hem in <sup>superficial</sup> subcutaneous tissue overlying  
right clavicle

no hem in <sup>ant</sup> post neck muscles

• 1/16" red punctate abrasion adjacent to l. corner of mouth and l. cheek



NAME OF DECEDENT: Unknown Female M.E.#: 819912555

EXAMINED BY: Margaret Pral DATE: 8/19/99

SCENE DESCRIPTION:

Apt. building. street level M.E. # Pa. 99 2858

apt. - D. in bedroom on floor. Body in on bedspread. Subapical head blood staining it where D's head was.

CLOTHING (ALL PERSONAL PROPERTY TO P.O. # \_\_\_\_\_)

knitwear - pants

BODY POSITION: supine on floor.

RIGOR MORTIS: (DESCRIBE LOCATION & INTENSITY) early broken

LIVOR MORTIS: (DESCRIBE COLOR, DISTRIBUTION, BLANCHING, FIXED)

metal

grossly inappropriate for position turned over when discovered by husband.

BODY TEMPERATURE (DATE/TIME/METHOD) 90 8-18-99 9:45 p Temp

AMBIENT TEMPERATURE (DATE/TIME) 82 8-18-99 9:45 p Temp

DECOMPOSITION AND ARTIFACTS: none observed

IDENTIFYING MARKS (SCARS, TATTOOS, ETC.) none observed

OTHER OBSERVATIONS/TRAUMA: - petechiae both eyes  
Dimple of face

- (L) upper arm bruise
- (L) lateral chest
- (R) elbow - laceration

[Signature]  
INVESTIGATOR

SUPPLEMENTAL CASE INFORMATION

OFFICE OF CHIEF MEDICAL EXAMINER  
CITY OF NEW YORK

Name of (deceased) (D) C. F. H. M.E. # 99-2858

Supplemental Information Date 8-13-99 TIME \_\_\_\_\_

Information Source: Det. Withers at scene

Address: \_\_\_\_\_ Tel. (\_\_\_\_) \_\_\_\_\_

Contact via: Telephone  Personal Interview  Correspondence

Contact Initiated by: Informant  Undersigned

29 H. female DOA at scene.  
Det. states husband last saw D early today and discovered D. under a sofa at about 6 PM. How D. ended. under the sofa is unk. However, police found blood on a pillow in another bedroom. D. has no known medical or psych history.  
CSA at scene 99/1714 Det Henry.

*[Handwritten signature]*